



CBCT Management of Previously Treated Mandibular Incisor with Extensive Internal Root Resorption: A Case Report

Ruth Pérez Alfayate^{a,*}, Ana Suarez^b, Juan Algar Pinilla^a

^aDepartment of Endodontics, School of Dentistry, Universidad Europea de Madrid, Madrid, Spain

^bDepartment of Clinical Dentistry, School of Dentistry, Universidad Europea de Madrid, Madrid, Spain

ARTICLE INFO

Article history:

Received 21 October 2020

Received in revised form 01 December 2020

Accepted 14 December 2020

Available online 20 December 2020

Keywords:

Instrumentation

Root canal obturation

Root resorption

ABSTRACT

This case report describes a central mandibular incisor's retreatment. Follow-up with perforating internal root resorption managed using a reciprocating file and obturated with down-pack and backfill technique, a surgical approach to seal the perforation. The medical history was non-contributory, and he had a history of traumatic injury resolved by a general dentist one year before. Tooth (4.1) presented pain and, after inspection and exploration, the clinical diagnosis was established as a previously-treated tooth with apical periodontitis. During periodic clinical and radiographic follow-up, the patient remained symptom-free, meeting functional expectations after eight years. Understanding the pathology and knowing the techniques to manage it could help recover the function of teeth considered lost.

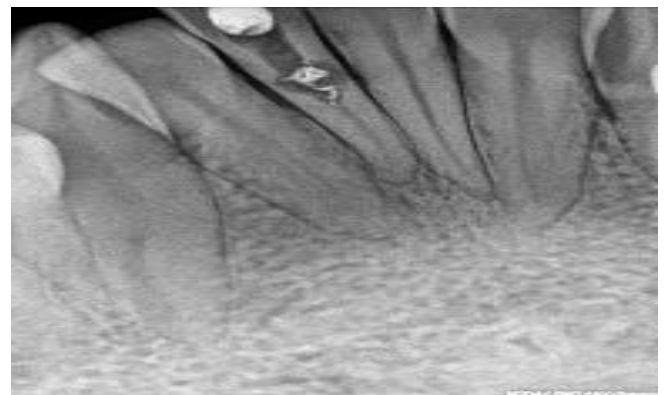
1. Introduction

In 1830 Bell described the concept of Internal root resorption (IRR) and has been defined as "the progressive destruction of intraradicular dentin of the canal walls as a result of clastic activities developed by odontoclast when a damaged of the predentin and odontoblasts layers have been previously established".^[1] Many injurious events such as trauma,^[2] caries and periodontal infection,^[3] heat,^[4] calcium hydroxide procedures,^[5] vital root resection,^[5] anachoresis,^[6] cracked teeth,^[7] orthodontic treatment,^[8] and dens invaginatus^[9] have been described as causes for damage of this two layers that could lead to IRR.^[4] Within all of these, traumatic events have been described as the main event involved in the initiation of this process (43%), followed by caries (25%) and periodontal infections (14%).^[10] This pathology's prevalence has not been well established, but the estimated frequency is 0.01-1% (patients affected).^[11] This event is a challenge for the clinician, not only for differential diagnosis but also for treatment difficulties and prognosis, increasing as the IRR development leads to thinner walls.

2. Case Presentation

A 21-year-old caucasian healthy male was referred for endodontic treatment of the mandibular right central incisor. The chief complaint was a

pain when biting and crown discoloration since a root canal treatment of this tooth was achieved one year before due to a traumatic event. The crown of tooth 4.1 presented discoloration, and the tooth presented tenderness to palpation and percussion compared to the adjacent teeth. The cold sensitivity test was negative. No probing or sinus tract was observed. A previous root canal treatment and a widening of the canal consistent with an advanced IRR of 4.1 were noted (Fig. 1).



* Corresponding author. Ruth Pérez Alfayate

E-mail address: Ruth.perez@universidadeuropea.es

Department of Endodontics, School of Dentistry, Universidad Europea de Madrid, Madrid, Spain

<http://doi.org/10.30485/IJSRDMS.2020.254227.1095>



Fig. 1. Periapical radiograph showing a previously treated tooth with IRR.

As the lesion presented a continuation with the root canal, this was described as an IRR. The lesion's configuration suggested the presence of a communication between the canal wall and the periodontal ligament. A CBCT was indicated to confirm a possible perforation, but the patient didn't accept economic reasons. A clinical diagnosis was established of the

previously-treated tooth with apical periodontitis. The primary purpose of treatment was to remove the infection and allow periapical healing. The tooth was isolated with a rubber dam, and access was gained to the pulp chamber. Working length (WL) was established using a size 10 K-file and an electronic apex locator (Root ZX Mini, JJ Morita) to 20mm (Fig. 2).

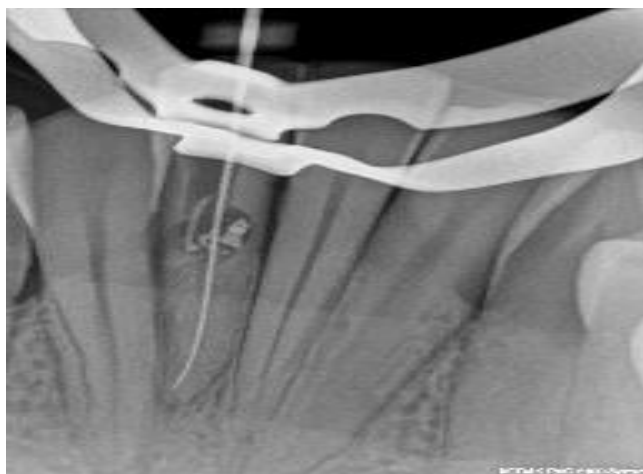

Fig. 2. Conductometry radiograph showing the working length.

Instrumentation was applied with a Reciproc 25 (VDW, München, Germany) to eliminate the gutta-percha present inside the canal and prepare de apical third. The file was used following the manufacturer's instructions in reciprocating motion, using a Reciproc motor (VDW, München, Germany). Irrigation with 5.25 % sodium hypochlorite (NaOCl) solution was used. For the final irrigation, 1 mL of 17% EDTA (Irri-S; VDW) ultrasonically activated in three 20-second cycles, and final irrigation with 5.25% NaOCl was performed. The root canal was dried with paper points size 25/0.02

(Dentsply). Appreciation of blood-spots on the coronal portion of the paper points confirmed communication with the periodontal ligament. During the one-session treatment, the down pack of a reciprocal gutta-percha R25 (VDW) was achieved with BeeFill 2 in 1 System (VDW), followed by backfill with increments of 2mm of gutta-percha using the same device and a Machtou plugger (VDW-Zipperer) (Figs. 3A, 3B, 3C), and a temporary filling of the access cavity (Cavit. 3M ESPE AG Dental Products) (Fig. 3D).

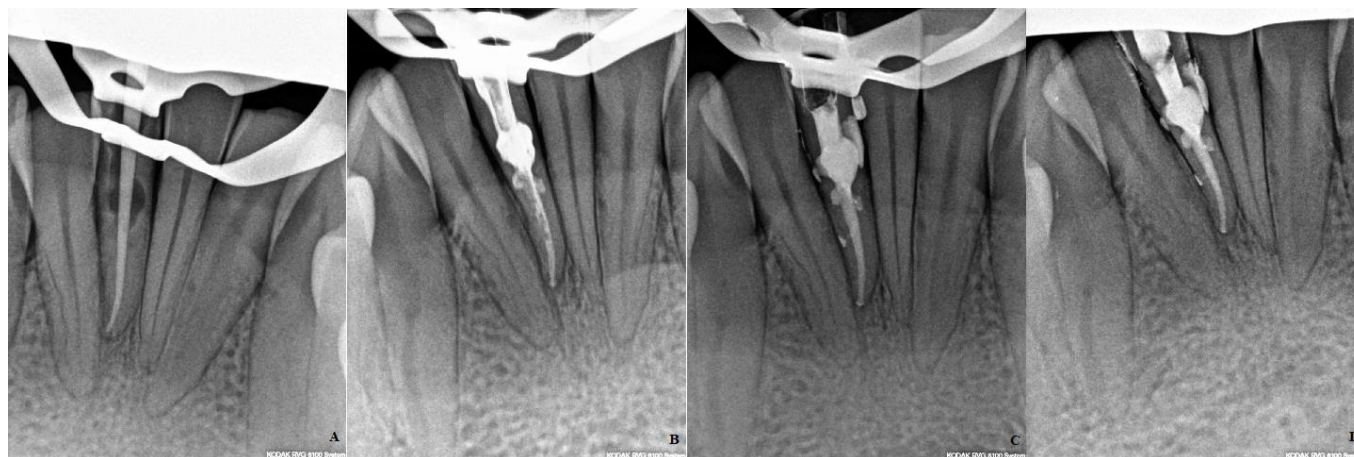

Fig. 3. A) gutta-percha cone fit B) down-pack C) backfill D) final radiograph with a provisional restoration.

The final restoration of the tooth was completed using composite in a second session. A flap was designed (intrasulcular incisions) to seal with composite the communication to the periodontal ligament due to the IRR perforation (Fig. 4). This perforation was at the cervical level of the root and

was not communicating with the bone. Thus the manipulation of the bone during the surgery was not needed. Follow-ups after 2, 6, 7, 8, and 10 years (Fig. 5) were achieved. The patient presented asymptomatic during the revisions, and the radiographic exploration didn't show any sign of pathology.

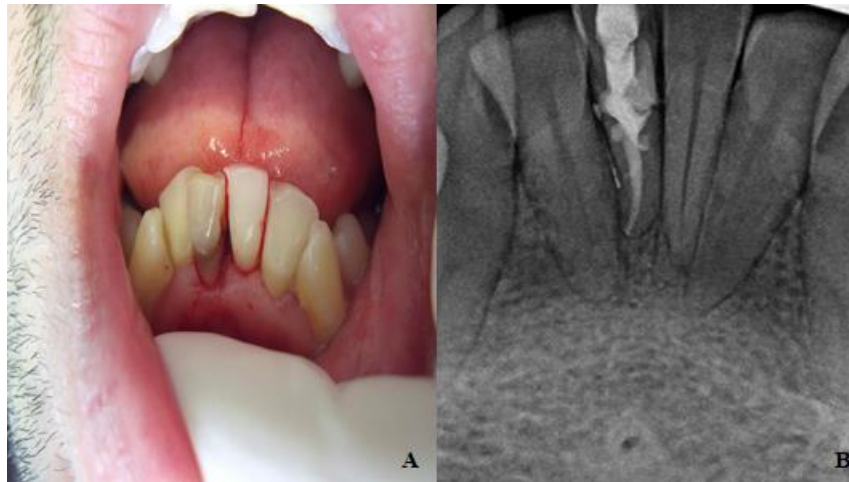


Fig. 4. A) clinical image of the intrasulcular flap design B) final radiograph after sealing the perforation.

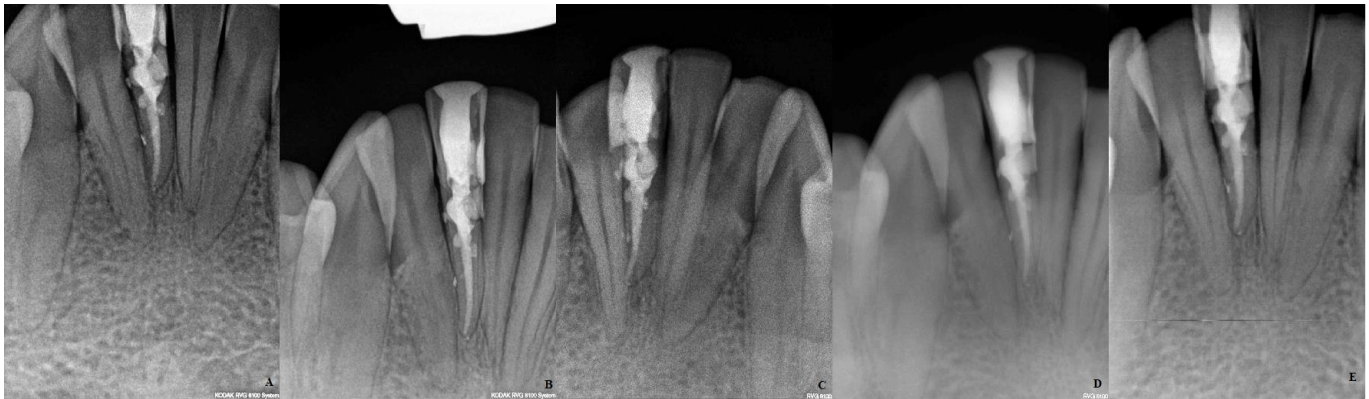

Fig. 5. A) follow up two years B) follow up six years C) follow up seven years D) follow up eight years E) 10 years.

3. Discussion

Internal resorption is rare and insidious.^[12] The aetiology and pathogenesis of this event are only partially understood. Many causes of damage to the protective odontoblasts and predentin layer, leading to exposure of the underlying mineralized dentin to odontoclasts, and the possible consequence of IRR have been described in the literature as mentioned before.^[4,11] A dental trauma event was added to this patient's dental history and therefore assuming it as the cause for the IRR to develop, that would continue. At the same time, there is a vascular supply to odontoclasts. In this case, this vascular input was eliminated once the primary treatment was established by a general dentist, preventing the loss of the tooth due to this reason, but allowing microorganisms to colonize the root canal system because of the lack of sealing during the treatment, permitting a secondary pathology to be established (apical periodontitis).

One of the difficulties during the treatment described in the literature^[14] of an IRR appears during the instrumentation management. It can occur because the IRR can act as a ledge into the root canal system that prevents instruments from achieving the most apical area, therefore increasing treatment time. A one-single file system as Reciproc (VDW) can help during the instrumentation phase since it reduces the time of the procedure, not only for the number of instruments used but also for the difficulty bypassing the area of the resorption. Regarding the irrigation protocol, the literature especially insists on its importance during an IRR treatment due to no instrument reaching the lesion walls. Thus, activation of the irrigants, such as ultrasonically activation, is needed to completely get chemical disinfection^[15] and prevent apical pathology.

Nevertheless, some limitations were present in this clinical report and must be taken into consideration. First, to mention is that the diagnosis and treatment plan could be compromised in the absence of a Cone-beam computerized tomography (CBCT) evaluation. CBCT has shown to be an excellent tool for the diagnosis and differential diagnosis of root resorptions. They can be observed as 3D images, giving a better idea of the prognosis, and designing the treatment plan.^[16] Dealing with the patients' circumstances, such as economic reasons, is a reality of the clinician's routine, as in this case, a CBCT could not be performed. Even nowadays, the materials recommended for the obturation of this type of root canal system are those based on calcium silicate due to their improvement on the resistance to fracture of these teeth; some of them can lead to discoloration of the crown,^[17] thereby recommending the use of the types that don't produce this event (Biodentine)^[18] or warm obturation techniques with gutta-percha.^[17] In this clinical report, the obturation phase was achieved with gutta-percha. At the moment of the treatment, the only calcium silicate-based cement available was Mineral trioxide aggregate (MTA) and would add more discoloration to a tooth in an aesthetic area. Also, the use of a bioceramic material would avoid the second surgery phase.

4. Conclusion

Using a reciprocating file can facilitate IRR treatment allowing more time to irrigation protocols that will enhance the prognosis of teeth with this pathology due to disinfection and preventing apical periodontitis with three-dimensional obturation of the root canal system.

Conflict of Interest

The authors declared that there is no conflict of interest.

Acknowledgements

This research received no specific grant from any funding agency in the public, commercial, or not-for-profit sectors.

References

- [1] Gulabivala K, Searson LJ. Clinical diagnosis of internal resorption: an exception to the rule. *International endodontic journal*. 1995;28(5):255-60. <https://doi.org/10.1111/j.1365-2591.1995.tb00310.x>.
- [2] Andreasen JO. Luxation of permanent teeth due to trauma A clinical and radiographic follow-up study of 189 injured teeth. *European Journal of Oral Sciences*. 1970;78(1-4):273-86. <https://doi.org/10.1111/j.1600-0722.1970.tb02074.x>.
- [3] Rabinowitch BZ. Internal resorption. *Oral Surgery, Oral Medicine, Oral Pathology*. 1972;33(2):263-82. [https://doi.org/10.1016/0030-4220\(72\)90396-9](https://doi.org/10.1016/0030-4220(72)90396-9).
- [4] Patel S, Ricucci D, Durak C, Tay F. Internal root resorption: a review. *Journal of endodontics*. 2010;36(7):1107-21. <https://doi.org/10.1016/j.joen.2010.03.014>.
- [5] Cabrini RL, Maisto OA, Manfredi EE. Internal resorption of dentine: histopathologic control of eight cases after pulp amputation and capping with calcium hydroxide. *Oral Surgery, Oral Medicine, Oral Pathology*. 1957;10(1):90-6. [https://doi.org/10.1016/S0030-4220\(57\)80120-0](https://doi.org/10.1016/S0030-4220(57)80120-0).
- [6] Penido RS, Carrel R, Chialastri AJ. The anachoretic effect in root resorption: report of case. *The Journal of pedodontics*. 1980;5(1):85.
- [7] Walton RE, Leonard LA. Cracked tooth: an etiology for “idiopathic” internal resorption?. *Journal of endodontics*. 1986;12(4):167-9. [https://doi.org/10.1016/S0099-2399\(86\)80056-5](https://doi.org/10.1016/S0099-2399(86)80056-5).
- [8] Silveira FF, Nunes E, Soares JA, Ferreira CL, Rotstein I. Double ‘pink tooth’ associated with extensive internal root resorption after orthodontic treatment: a case report. *Dental Traumatology*. 2009;25(3):e43-7. <https://doi.org/10.1111/j.1600-9657.2008.00755.x>.
- [9] Pérez-Alfayate R, Mercadé M, Vera J. Relationship between internal root resorption and dens in dente. *Journal of Clinical and Experimental Dentistry*. 2020;12(8):e800-e804. doi: 10.4317/jced.56944.
- [10] Caliřkan MK, Türkün M. Prognosis of permanent teeth with internal resorption: a clinical review. *Dental Traumatology*. 1997;13(2):75-81. <https://doi.org/10.1111/j.1600-9657.1997.tb00014.x>.
- [11] Haapasalo M, Endal U. Internal inflammatory root resorption: the unknown resorption of the tooth. *Endodontic topics*. 2006;14(1):60-79. <https://doi.org/10.1111/j.1601-1546.2008.00226.x>.
- [12] Thomas P, Krishna Pillai R, Pushparajan Ramakrishnan B, Palani J. An insight into internal resorption. *International Scholarly Research Notices*. 2014. <https://doi.org/10.1155/2014/759326>.
- [13] WEDENBERG C, LINDSKOG S. Evidence for a resorption inhibitor in dentin. *European Journal of Oral Sciences*. 1987;95(3):205-11. <https://doi.org/10.1111/j.1600-0722.1987.tb01832.x>.
- [14] de Souza SN, Marques AA, Sponchiado-Júnior EC, Garcia LD, da Frota MF, de Carvalho FM. Technological advances in endodontics: treatment of a mandibular molar with internal root resorption using a reciprocating single-file system. *Gen Dent*. 2017;65(3):e5-8.
- [15] Ulusoy ÖI, Savur IG, Alaçam T, Çelik B. The effectiveness of various irrigation protocols on organic tissue removal from simulated internal resorption defects. *International endodontic journal*. 2018;51(9):1030-6. <https://doi.org/10.1111/iej.12919>.
- [16] Patel S, Durack C, Abella F, Roig M, Shemesh H, Lambrechts P, Lemberg K. European Society of Endodontology position statement: the use of CBCT in endodontics. *International Endodontic Journal*. 2014;47(6):502-4. <https://doi.org/10.1111/iej.12267>.
- [17] Türker SA, Uzunođlu E, Sungur DD, Tek V. Fracture resistance of teeth with simulated perforating internal resorption cavities repaired with different calcium silicate-based cements and backfilling materials. *Journal of endodontics*. 2018;44(5):860-3. <https://doi.org/10.1016/j.joen.2018.01.019>.
- [18] Vallés M, Mercadé M, Duran-Sindreu F, Bourdelande JL, Roig M. Influence of light and oxygen on the color stability of five calcium silicate-based materials. *Journal of endodontics*. 2013;39(4):525-8. <https://doi.org/10.1016/j.joen.2012.12.021>.

How to Cite this Article: Pérez-Alfayate R, Suarez A, Pinilla JA. CBCT Management of Previously Treated Mandibular Incisor with Extensive Internal Root Resorption: A Case Report. *International Journal of Scientific Research in Dental and Medical Sciences*, 2020;2(4):141-144. doi:10.30485/IJSRDMS.2020.254227.1095.